

## **A Retroperitoneal Peritoneal Cyst, A Rare Cystic Lesion, Case Report**

Anwar Al-Neweiri<sup>1</sup>, Mohammad Al-Jafari<sup>2</sup>, Sadeen K. Zein Eddin<sup>3</sup>,  
Mohammad Al Mse'adeen<sup>4</sup>, SajaZuaiter<sup>5</sup>, Ahmad Nasrallah<sup>6</sup>,  
Mohammad Abu-Jeyyab<sup>7\*</sup>

1-General Surgery Department ,Al-Basheer Hospital, Amman, Jordan

2,3,4,5,7-School of Medicine, Mutah University, Al-Karak, Jordan.

6-General Surgery Department, Prince Hamza Hospital, Amman, Jordan.

### **Abstract**

#### **Background**

Retroperitoneal cystic masses are benign fluid filled lesions arising within the retroperitoneal space surrounding the organs of the compartment. Peritoneal cysts are defined as tumors of the abdomen and pelvic peritoneum. Both are rare conditions that commonly assume an asymptomatic presentation, posing a challenge in diagnosis.

#### **Case presentation**

A 42-year-old male was admitted to the surgical ward for right lower abdominal pain which had been present since one year. Ultrasound revealed that the mass was cystic in consistency and localized to the right side of the urinary bladder containing debris and multiple calcifications. Intraoperatively, a retroperitoneal mass (cyst) about (9×9cm) in size was found adherent to the surrounding tissue, and when opened, fluid and mucus gelatinous material with debris and two staghorn stones (3×3cm) were identified inside it. The mass extended downward through the right femoral canal to the thigh. An incision below the right inguinal ligament was done, and another stag horn of (3×3cm) size was found inside it. Total excision of the whole cyst was performed. Fluid was sent for cytopathology for microscopic examination, and the result was negative for malignancy.

#### **Conclusion**

A rare incidence of retroperitoneal peritoneal cyst grows to massive measures and thus leads to nonspecific abdominal symptoms. Total excision is the treatment of choice for this case.

**Keywords:** Retroperitoneal, peritoneal sac, cystic, ultrasound.

### **Introduction**

As the name denotes, retroperitoneal cystic masses are benign fluid filled lesions arising within the retroperitoneal space surrounding the organs of the compartment. It is a rare condition with an incidence of 1/5750 to 1/250,000 (1). According to many reports, there are no clinical signs which are pathognomonic of retroperitoneal cyst. It is predominantly an asymptomatic condition, yet approximately half of the patients present with nonspecific symptoms such as vague abdominal pain and bloating (1,2). For this reason, the cyst is discovered incidentally. However, due to the massive space the retroperitoneum occupies, these sacs tend to greatly augment in size eventually causing significant manifestations and complications (3). The diagnosis is made by using radiographic investigations with computed tomography (CT) scan being the most useful modality for narrowing down the potential list of differentials. Moreover, the treatment of choice is complete surgical excision. One case report suggests that incomplete excision is associated with a tremendous rate of local recurrence (4).

Similarly, cystic lesions arising from the peritoneum are less commonly encountered. Peritoneal cysts are defined as tumors of the abdomen and pelvic peritoneum (5). These sacs usually present in women in the childbearing age as a complication of extremely rare disease entities. The most common clinical presentation caused by these lesions is frequently nonspecific with progressive pelvic pain and palpable abdominal mass (6). Less than half of the cases are diagnosed accidentally underlining the frequency of asymptomatic patients (6).

This case report aims to share a rare case of retroperitoneal peritoneal cyst. Despite the continuous advancement in numerous imaging modalities, this condition still poses diagnostic as well as therapeutic challenges. To this day, various case reports presented the different types of retroperitoneal cystic masses, but to our knowledge only two cases of this specific kind are found in literature.

### **Case Presentation**

A 42 year-old male was admitted to the surgical ward for right lower abdominal pain which had been present since one year. Pain was aching in nature. Its intensity increased with time, and it was exacerbated by walking. In the last three months, pain started to radiate to the right lower limb, mainly to the anterior and medial aspects of the right thigh.

Later, the patient had started limping in the right lower limb. At this point, pain was not relieved by analgesics. There was no history of change in bowel habits, anorexia, or loss of weight. The patient had a history of newly discovered hypertension, controlled by treatment. He also has a previous history of hiatus hernia and is now on treatment for duodenal ulcer. Additionally, the patient was a heavy smoker. On physical examination, the abdomen was soft and lax, and there was a palpable mass in the right lower abdomen. On deep palpation, the mass was not tender, oval in shape, and about 8\*10 cm in size. It also had a smooth surface, and the edges were well defined in the upper part but ill-defined in the lower part. The mass was not pulsatile, not compressible, and not mobile. Furthermore, there was multiple right inguinal lymph nodes enlargement.

### Investigations

Blood tests including CBC, KFT, LFT, and URINALYSIS were performed and were normal.

### Radio-imaging

Regarding imaging, a chest x-ray was done and it was normal (figure1). A Plain abdomen showed that there were clusters of calcifications on the right side of the pelvis and clusters of calcifications medial to the right head of the femur (figure 2). After giving the IV contrast, both kidneys, ureters, and urinary bladder are normal with symmetrical excretion, and no residual urine (figure 3). On abdominal ultrasound and abdominal CT scan the mass size was (8.5x8.5cm).in addition, ultrasound reveals that the mass was cystic in consistency and localized to the right side of the urinary bladder containing debris and multiple calcifications (figure 5).

Abdominal and Pelvic C.T scans with and without contrast were done and they revealed that the liver, spleen, pancreas, and both suprarenal glands were normal. There was mainly cystic structure to the right side of the urinary bladder containing calcification not connected to it, suspected that the mass originated from pelvic muscle (figure 5).

Intraoperative, after preparing the patient and under general anesthesia a lower midline incision was done. The findings were retroperitoneal mass (cyst) about (9x9cm) in size adherent with the surrounding tissue. When the cyst had been opened, serous fluid and mucus gelatinous material with debris and 2 stag horn stones (3x3cm) each containing inside it were identified. The mass extended downward through the right femoral canal to the thigh and an incision below the right inguinal ligament was done. The skin was opened in layers, the size of this part is about (4x4x6 cm) and another stag horn of (3x3cm) size was found inside it. Total excision of the whole cyst was done. Fluid was sent for cytopathology for microscopic examination and the result was Negative for malignancy; benign mesothelial cells. Regarding the cyst and Inguinal lymph node samples that were sent for histopathology; mesothelium lined peritoneal cyst containing 3 nodular white calcified bony masses {3x3cm} inside it and was Negative for malignancy. Inguinal lymph node histopathology showed reactive lymphoid hyperplasia

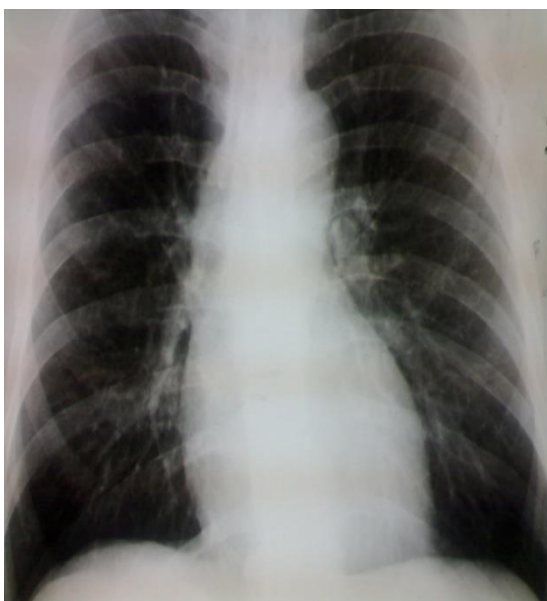

figure1 : Chest x-ray

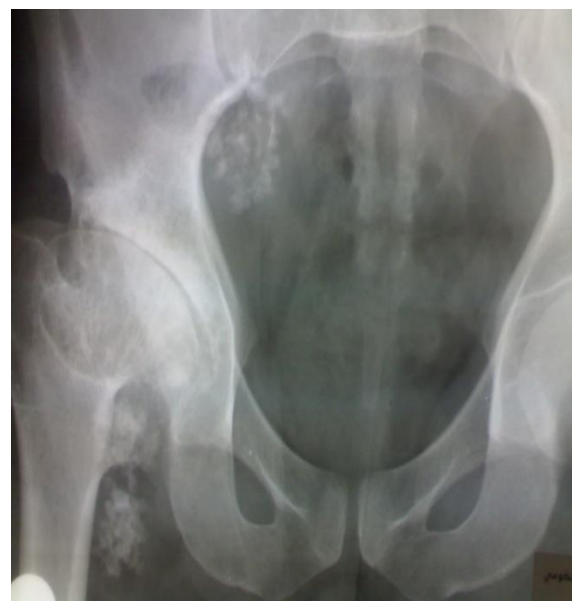

figure2: Plain abdominal radiograph

figure3: Plain abdominal radiograph

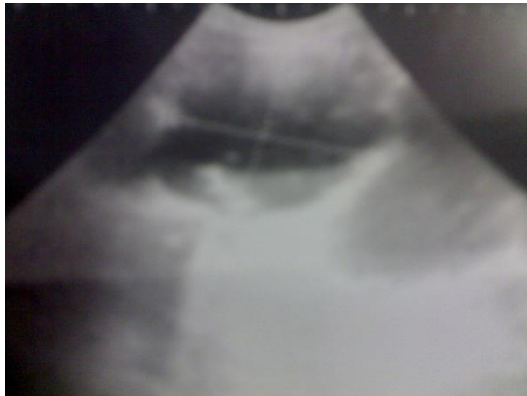

Figure 4 :Abdominal ultrasound

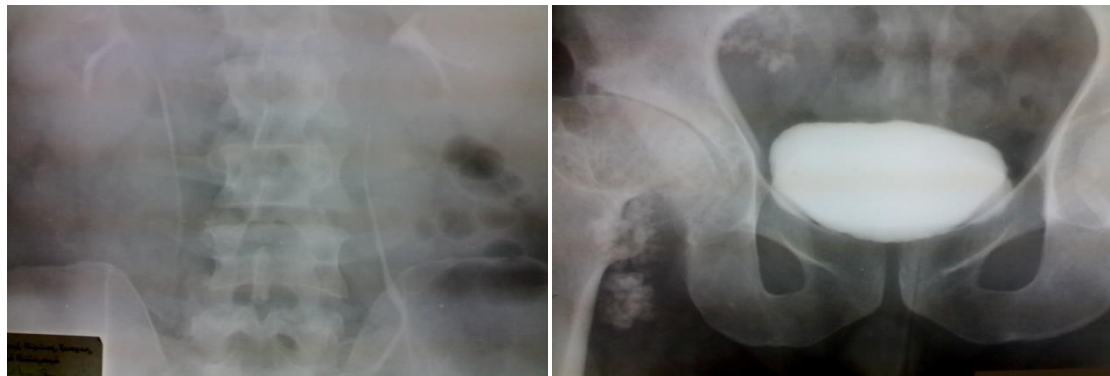
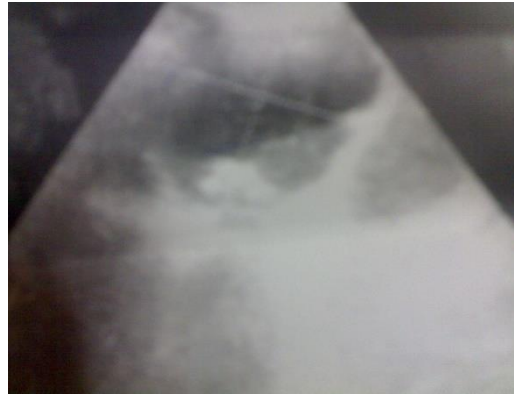
Figure 3: intravenous urogram

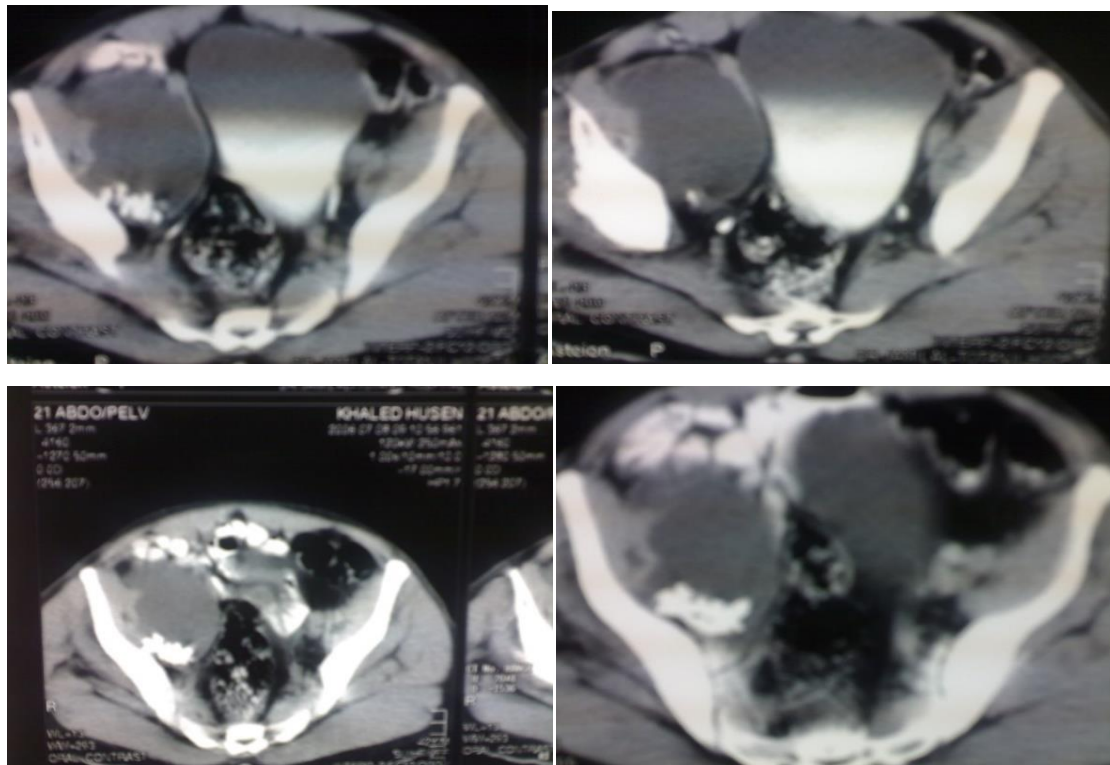


Figure 5: Abdominal and pelvic CT scan

## Discussion

Benign multicystic peritoneal mesothelioma is a rare benign tumor originating from the peritoneum, affecting mostly young, fertile women, and it is very rare in men (7). The incidence of the disease is 0.15/per 100,000 annually, which makes it challenging to diagnose and treat (8).

Handfield-Jones; Texas.Univers.USA; defined retroperitoneal-peritoneal cysts as those cysts lying in the retroperitoneal fatty tissue which have no apparent connection with any adult anatomical structure save by areolar tissue”.

This studied case is unique because the combination of retroperitoneal and peritoneal cyst in the same situation is rarely reported. Retroperitoneal peritoneal cyst in the literature reported just two cases. Also, the gender of the patient, in this case, makes it rare as the disease doesn't occur in males routinely. Moreover, the three staghorn stones that were found after excision increase the uniqueness of this case.

The uncertainty regarding their nature is reflected in the terminology used for these lesions in the literature; they have been called benign multicystic mesothelioma, cystic mesothelioma, multilocular peritoneal inclusion cysts, inflammatory cysts of the peritoneum, and postoperative peritoneal cyst. Associated risk factors include endometriosis and pelvic inflammatory disease in women, and prior abdominal surgery in both genders (9).

Moreover, the pathogenesis of this condition is still controversial until now. However, According to a study done by Khurram et al. (8), There are three hypotheses have been proposed, First, the disease is secondary to a reactive process, and second, some authors believe the origin to be neoplastic. The third theory may be a hormonal hypothesis, within which the event and progression of BMPM(Benign Multicystic Peritoneal Mesothelioma) are tightly linked to its sensitivity to sex hormones. This theory is supported by the evidence of upper incidence in women during their reproductive age and also the responsiveness of BMPM to certain endocrine agents like tamoxifen and gonadotropin-releasing hormone analogs. Some genetic and familial associations have also been documented.

Khurram et al. (8) said in their study "Two of our cases had a family history of colon, breast, and lung cancer and leukemia, respectively". The potential for malignant transformation in patients with benign multicystic peritoneal mesothelioma is low(7). On the other hand, there were only two cases reported in the literature.

The diagnosis of benign cystic peritoneal mesothelioma is difficult(10). In most cases, the diagnosis is made incidentally during routine investigation or surgery for another purpose.

Radiological modalities including ultrasonography, CT, and MRI may detect the lesions but cannot differentiate them from other cystic lesions. Exploratory laparoscopy is the most accurate diagnostic method because it allows local biopsy of the suspected tissue.

As the recurrence rate is high when incomplete resection of the cyst is done. As a result, complete resection is recommended. An aggressive surgical approach including cytoreductive surgery with peritonectomy is also recommended to avoid recurrence. Because malignant transformation is reported in 2 cases, some choose aggressive surgery followed by heated intraperitoneal chemotherapy (HIPEC).

## Conclusion

Benign multicystic peritoneal mesothelioma is a rare benign tumor originating from the peritoneum, affecting mostly pre-menopausal women. The diagnosis of this case is difficult.Surgery remains the mainstay of treatment.

## Acknowledgments

This research was mentored and supervised by the Mutah Research and Audit Society (MRAS).

## References

- 1) A;, V. A. G. V. G. A. M. J. P. (n.d.). Retroperitoneal pelvic cyst: A diagnostic and therapeutic challenge. Journal of obstetrics and gynaecologyCanada : JOGC = Journal d'obstetrique et gynecologie du Canada : JOGC. Retrieved July 2, 2022, from <https://pubmed.ncbi.nlm.nih.gov/23470067/>
- 2) Abedini, L., Hosseinpour, R., Mehrabi, S., Hejazinia, S., & Yavari Barhaghtalab, M. J. (2022, February 16). An asymptomatic huge primary retroperitoneal pseudocyst: A case report and review of the literature. BMC surgery. Retrieved July 2, 2022, from <https://www.ncbi.nlm.nih.gov/pmc/articles/PMC8851848/>

- 3) Hospital, F. the \*J. H. (n.d.). Retroperitoneal cyst of Müllerian origin: A case report and ... : Urogynecology. LWW. Retrieved July 2, 2022, from [https://journals.lww.com/fpmrs/Abstract/2007/06000/Retroperitoneal\\_Cyst\\_of\\_Müllerian\\_Origin\\_\\_A\\_Case.9.aspx](https://journals.lww.com/fpmrs/Abstract/2007/06000/Retroperitoneal_Cyst_of_Müllerian_Origin__A_Case.9.aspx)
- 4) Maurya, S. K., Bhot, F. B., Ghosh, D. K., & Nayak, V. M. (2003, January). Retroperitoneal cyst. Medical journal, Armed Forces India. Retrieved July 2, 2022, from <https://www.ncbi.nlm.nih.gov/pmc/articles/PMC4925779/?fbclid=IwAR0fRqr63Znx8qtl-pOdNX1yxiEyXrpqWjgzjHT-YbMxSoQRnDodQhNJgAA>
- 5) UchikovaE;MilchevN;DimitrovaE;AnaviB;Uchikov A; (n.d.). [peritoneal cyst--a case report]. Akusherstvoiginekologija. Retrieved July 2, 2022, from <https://pubmed.ncbi.nlm.nih.gov/12858488/>
- 6) W;, N. A. B.-S. M. A. M. T. S. (n.d.). Peritoneal inclusion cysts as a diagnostic and treatment challenge. Ginekologiapolska. Retrieved July 2, 2022, from <https://pubmed.ncbi.nlm.nih.gov/34541630/>
- 7) György, A., Schmal, F., Szabó, H., Tóth, L. B., & Lukovich, P. (2019). Benign multicystic peritoneal mesothelioma [Benign multicystic peritoneal mesothelioma]. *Orvosihetilap*, 160(21), 839–843. <https://doi.org/10.1556/650.2019.31402>
- 8) Khurram, M. S., Shaikh, H., Khan, U., Edens, J., Ibrar, W., Hamza, A., Zaka, A., Bano, R., & Hadid, T. (2017). Benign Multicystic Peritoneal Mesothelioma: A Rare Condition in an Uncommon Gender. *Case reports in pathology*, 2017, 9752908. <https://doi.org/10.1155/2017/9752908>.
- 9) Chand, M. T., Edens, J., Lin, T., Anderson, I., & Berri, R. (2020). Benign multicystic peritoneal mesothelioma: literature review and update. *Autopsy & case reports*, 10(3), e2020159. <https://doi.org/10.4322/acr.2020.159>.
- 10) Khuri, S., Gilshtein, H., Abboud, W., Assalia, A., & Kluger, Y. (2012). Benign cystic mesothelioma of the peritoneum: a rare case and review of the literature. *Case reports in oncology*, 5(3), 667–670. <https://doi.org/10.1159/000346187>.